Influence Of Posterior Teeth On The Anatomical Location Of Fracture Line In Condylar Fractures – A Cross Sectional Study Using Digital Panaromic Radiographs

M.S. Jothish[1], P. Srinivasan[2], K. Janarthanan[3], S. Manikandaswamy[4], Fayeez Abdullah[5], D. Thirumaran[6]

[2,3] Cuddalore Government Dental College, Department of Oral and Maxillofacial Surgery. [5,6] Cuddalore Government Dental College, Department of Prosthodontics

Επιρροή των οπισθίων δοντιών στην ανατομική εντόπιση της γραμμής του κατάγματος σε κατάγματα των κονδύλων – Μια μελέτη χρονικής στιγμής με χρήση ψηφιακών πανοραμικών ακτινογραφιών

M.S. Jothish[1], P. Srinivasan[2], K. Janarthanan[3], S. Manikandaswamy[4], Fayeez Abdullah[5], D. Thirumaran[6]

[2,3] Cuddalore Government Dental College, Department of Oral and Maxillofacial Surgery. [5,6] Cuddalore Government Dental College, Department of Prosthodontics

DOI: https://dx.doi.org/10.54936/haoms2413742

Original Study
Πρωτότυπη Εργασία

SUMMARY: *Background:* Condylar fracture have been probably the most mismanaged fractures throughout history. They were either not treated because of improper diagnosis or were managed minimally using external bandages to immobilise the mandible. If left untreated, condylar fractures lead to temporomandibular disorders like ankylosis, dysfunction, chronic dislocation and chronic pain. Even though many authors classify condylar fractures based on their location, no literature currently exists in determining the exact cause which ascertains the location of the fracture line. In this study we attempted to analyse if the presence or absence of posterior teeth is in any way related to the anatomic level of condylar fractures.
Materials and Methods: 200 Orthopantomographic images of patients who presented to the department of oral and maxillofacial surgery with condylar fracture from the year 2017-2021 were collected from the medical records department. Out of these 200 OPGs 170 images where finally selected based on the inclusion criteria. Presence or absence of posterior teeth and the total number of missing posterior teeth were calculated and subjected to statistical analysis.
Results: Diacapitular fractures were common in patients with no missing teeth and sub condylar fractures were found in patients with absence of posterior teeth hence

ΠΕΡΙΛΗΨΗ: *Ιστορικό:* Το κάταγμα κονδύλου είναι ίσως από τα πιο κακοδιαχειρισμένα κατάγματα σε όλη την ιστορία. Είτε δεν αντιμετωπίζονταν λόγω ακατάλληλης διάγνωσης είτε αντιμετωπίζονταν ελάχιστα με τη χρήση εξωτερικών επιδέσμων για την ακινητοποίηση της κάτω γνάθου. Εάν αφεθούν χωρίς θεραπεία, τα κατάγματα των κονδύλων οδηγούν σε κροταφογναθικές διαταραχές όπως αγκύλωση, δυσλειτουργία, χρόνιο εξάρθρημα και χρόνιο πόνο. Παρόλο που πολλοί συγγραφείς ταξινομούν τα κατάγματα των κονδυλίων με βάση τη θέση τους, δεν υπάρχει βιβλιογραφία προς το παρόν για τον προσδιορισμό της ακριβούς αιτίας που να επιβεβαιώνει τη θέση της γραμμής κατάγματος. Σε αυτή τη μελέτη επιχειρήσαμε να αναλύσουμε εάν η παρουσία ή η απουσία οπίσθιων δοντιών σχετίζεται με οποιονδήποτε τρόπο με το ανατομικό επίπεδο των καταγμάτων των κονδύλων.
Υλικά και Μέθοδοι: 200 Ορθοπαντομογραφικές (OPG) εικόνες ασθενών που παρουσιάστηκαν στο τμήμα στοματικής και γναθοπροσωπικής χειρουργικής με κάταγμα κονδύλου από το έτος 2017-2021 συγκεντρώθηκαν από το τμήμα ιατρικών αρχείων. Από αυτά τα 200 περιστατικά, 170 OPG επιλέχθηκαν τελικά με βάση τα κριτήρια εισαγωγής της μελέτης. Η παρουσία ή η απουσία οπίσθιων δοντιών και ο συνολικός αριθμός των οπίσθιων δοντιών που λείπουν υπολογίστηκαν και υποβλήθηκαν σε στατιστική ανάλυση.

[1] MDS, Oral and Maxillofacial Surgeon, Private Practitioner
[2] Head of the department
[3] Associate professor
[4] Private practioner
[5] Postgraduate student
[6] Postgraduate student

validating our hypothesis that the number of missing posterior teeth are indeed associated with the level of condylar fractures and that, missing maxillary posteriors, mandibular posteriors, premolars and molars all statistical significantly independently correlated with the level of condylar fracture.
Conclusion: In condylar fractures, the level of fracture line is influenced by the presence or absence of posterior teeth. The teeth are usually neglected as they are considered as an accessory aid and not an integral component of the facial skeleton. Proving that the teeth are involved in a complex mechanism which protects the Temporo- Mandibular joint from traumatic forces on the mandible will further solidify their position as an integral functional component and shift the focus towards preserving rather than removing them whenever possible.

KEY WORDS: *Condylar fracture, Fracture line, Orthopantomogram, Posterior teeth, Diacapitular fracture, Subcondylar fracture*

Αποτελέσματα: Τα διακεφαλικά κατάγματα ήταν συχνά σε ασθενείς χωρίς ελλείποντα δόντια και τα υποκονδυλικά κατάγματα βρέθηκαν συχνότερα σε ασθενείς με απουσία οπίσθιων δοντιών, επομένως επιβεβαιώνεται η υπόθεσή μας ότι ο αριθμός των οπίσθιων δοντιών που λείπουν συνδέεται όντως με το επίπεδο των καταγμάτων του κονδύλου και ότι η έλλειψη οπισθίων της άνω γνάθου, οπισθίων της κάτω γνάθου, προγομφίοι και γομφίοι, όλα ανεξάρτητα, σχετίζονται στατιστικά σημαντικά με το επίπεδο του κατάγματος του κονδύλου.
Συμπέρασμα: Στα κατάγματα των κονδύλων, το επίπεδο της γραμμής του κατάγματος επηρεάζεται από την παρουσία ή την απουσία οπίσθιων δοντιών. Τα δόντια συνήθως παραμελούνται καθώς θεωρούνται ως βοήθημα και όχι αναπόσπαστο συστατικό του σκελετού του προσώπου. Η απόδειξη ότι τα δόντια εμπλέκονται σε έναν περίπλοκο μηχανισμό που προστατεύει την κροταφογνάθική άρθρωση από τραυματικές δυνάμεις στην κάτω γνάθο θα καταδείξει περαιτέρω τη θέση τους ως αναπόσπαστο λειτουργικό συστατικό και θα αποτελέσει ένα ακόμη λόγο για τη διατήρησή τους αντί για την αφαίρεσή τους όποτε αυτό είναι δυνατόν.

ΛΕΞΕΙΣ ΚΛΕΙΔΙΑ: *Κάταγμα κονδυλίου, Γραμμή κατάγματος, Ορθοπαντομογραφία, οπίσθια δόντια, κάταγμα διακεφαλικό, κάταγμα υποκονδυλικό*

Paper received: 20/10/22 - Accepted: 3/2/23

Παρελήφθη: 20/10/22 - Έγινε δεκτή: 3/2/23

INTRODUCTION

Condylar fractures are defined as fractures that run from within or above the angle of the mandible into the sigmoid notch or the condylar head. They are found usually above the mandibular foramen (1). This fracture is indirect as opposed to other direct fractures because the force that breaks the condylar unit is transmitted from different areas of the mandibular column rather than falling directly on the condyle (2). Condylar fracture incidence ranged from 8 percent in the late 20th century to 44 percent in the early 21st century (3). This exponential growth could be attributed to the advent of high-speed cars and increased reliance on private transportation. Interpersonal violence is among the most frequent causes of condylar fracture. Condylar fractures occur more frequently in men than in women (4). While condylar fractures linked to falls are more common in women, work-related condylar fractures are more common in men (5). Paediatric condylar fractures are frequently caused by falls and sports-related accidents (6).
Multi-slice spiral computed tomography (MSCT) has a sensitivity of 100% which makes it the ideal diagnostic tool for identifying condylar fractures (7). But due to the high cost and limited availability, conventional radiographs like OPG are widely used clinically and also are equally sensitive for the detection of condylar fractures (8).
Historically speaking condylar fractures have been notoriously known for being poorly diagnosed and inadequately managed. They were either not treated since early diagnosis was not made, or they received minimum care by having the mandible immobilised with external bandages (9). For patients receiving open treatment, Al-Moraissi and Ellis' meta-analyses revealed that ORIF increased mandibular mobility, decreased postoperative discomfort, and enhanced occlusion (10). When compared to closed care, Chrcanovic et al. discovered that patients receiving ORIF had better functional outcomes (11).
Temporomandibular joint disorders such as ankylosis and dysfunction, malocclusion, chronic dislocation and pain on the injured as well as the non-injured side may also occur if condylar fractures are left untreated (12). If condylar fractures occur in children prior to completion of growth and are not properly managed, growth disturbances and asymmetry at multiple facial levels, including the orbits, cheeks, maxilla, and mandible may result (13).
With condylar fractures showing varied morphology and treatment options being circled with controversy, any new information gained in this field has considerable

significance. As there is a scientific lacuna in the literature surrounding the identification of condylar fracture and its anatomic variation, this study attempts to determine whether the presence or absence of posterior teeth has any influence on the level of condylar fracture.

MATERIALS AND METHODS

After obtaining ethical clearance, 200 Orthopantomographic images of patients (N=200) who presented to the department of oral and maxillofacial surgery with condylar fracture from the year 2017-2021 were collected from the medical records department. Out of these 200 OPGs 170 images where finally selected based on the criteria mentioned below.

INCLUSION CRITERIA:
- All condylar fracture patients OPGs above 13 years of age
- Both unilateral and bilateral condylar fractures
- Both isolated condylar fractures and condylar fractures associated with fracture of other parts of the mandible
- Condylar fractures associated with other facial bone fractures

EXCLUSION CRITERIA:
- OPGs of patients below 13 years of age
- OPGs of patients with mixed dentition
- OPGs of patients with posterior dental implants
- OPGs of patients with crown or bridges in posterior teeth
- OPGs of patients with associated lesions in the mandible
- OPGs with poor image quality
- Teeth which were grossly decayed so that they had no remaining crown structure were considered to be missing. Third molars were not included in the study.

Graph 1: Graphical illustration of associated fractures and their location

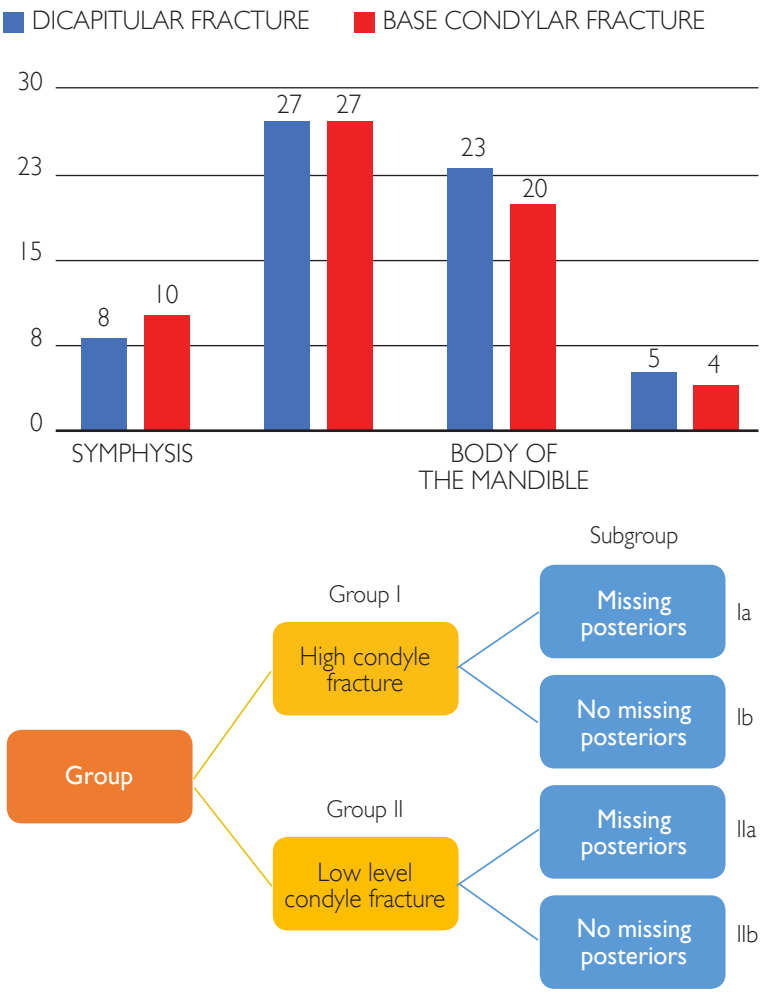

All samples were divided into two groups based on the Strasbourg osteosynthesis research group criteria into Diacapitular (high level) fractures and Fracture of the condylar base (low level fractures). The two groups were further divided into subgroups based on presence or absence of posterior teeth. The grouping is visualized and given in Graph 1

GROUP 1: High condyle fracture aka Diacapitular fracture where the fracture line starts in the articular surface and ends within the capsule and may sometimes extend outside the capsule.

GROUP 2: Low level condyle fracture. It is the fracture of the condylar base where the fracture line runs from the sigmoid notch and extends behind the mandibular foramen. The length of this line is more than half, below line A. (as seen in Strasbourg osteosynthesis research group classification).

STATISTICAL ANALYSIS:

Data regarding demographics, missing teeth of condylar fractures and associated fractures were entered into Microsoft Excel and analysed using IBM SPSS Statistics for Windows, Version 20 (IBM Corp., Armonk, N.Y., USA). Continuous variables were presented as mean ± standard deviation (SD). The comparison of Diacapitular and base condyle fractures was done using Mann Whitney test. The level of significance was determined at $p<0.05$.

RESULTS

Of the 170 OPGs that were assessed into two groups, the associated dentition with fractures is illustrated in graph 1. The distribution of mean and standard deviation of all variables of missing teeth is given in table 1. Significant difference was seen on comparing the mean

Table 1: Comparison of mean value of total missing teeth in the two group

	N	Mean	Std. Deviation
Missing upper teeth	170	.5000	1.37281
Missing Lower teeth	170	.7235	1.50346
Missing Premolar	170	.3647	1.17516
Missing Molars	170	.8765	1.59215
Total Missing	170	1.2412	2.55022
Condylar fractures	170	1.5000	.50148

Table 2: Comparison of mean values of upper teeth, lower teeth, premolars and molars in the two group

	Ranks				
	Condylar fractures	N	Mean Rank	Sum of Ranks	P Value
Missing upper teeth	Diacapitular	85	76.24	6480.50	
	Base condylar	85	94.76	8054.50	0.001
	Total	170			
Missing Lower teeth	Diacapitular	85	68.57	5828.50	
	Base condylar	85	102.43	8706.50	0.000
	Total	170			
Missing Premolar	Diacapitular	85	79.33	6743.00	
	Base condylar	85	91.67	7792.00	0.009
	Total	170			
Missing Molars	Diacapitular	85	67.28	5719.00	
	Base condylar	85	103.72	8816.00	0.000
	Total	170			

value of total missing teeth in the two groups; Diacapitular fractures had a mean of 67.57 while base condylar fractures had a mean of 103.43 (p=0.000). Comparison of mean values of upper teeth, lower teeth, premolars and molars in the two groups are given in table 2.

Table 2 shows that Mann Whitney U test revealed missing upper teeth, missing lower teeth, premolars and molars median scores were significantly lower in diacapitular fractures when compared to base condyle fractures. The u value, z value and p value for upper teeth (u= 2826.5, z= -3.3, p= 0.001), lower teeth (u=2173.5, z= -5.47, p=0.000), premolar (u=3088.0, z= -2.61, p=0.009) and molars (u=2064.0, z= -5.61, p=0.000) and all variables are statistically significant.

Fig 2 shows a mandibular column where R represents the ramus, F2 is the direction of force, G1- roof of glenoid fossa and FL- point of flexural stress. The results in Table 2 show that a Mann Whitney U test revealed total missing teeth median score were significantly lower in Diacapitular fractures compared to base condyle fractures and u value and z value for Diacapitular and Base condylar fractures are fractures are 2088.5, -5.359 respectively and statistically significant (p=0.000)

DISCUSSION

The mandibular condyle following trauma, fractures at different anatomical locations. Various classifications have been put forth by different authors to subclassify these fractures to the condylar process. Loukota RA et al in 2005 gave a subclassification of condylar fractures based on location which was adopted by the Strasbourg osteosynthesis research group for classifying condylar fractures (14). Different authors over the years gave their own classification for condylar fractures but no effort was made to identify why the condyle fractured at different anatomical areas (15-17). The purpose of this study was to identify whether the absence of missing

posterior teeth has an influence on level of condylar fractures.

According to the column principle, the mandible transmits forces of any intensity through its body, ramus and through the condyle upwards into the temporal bone and through the dentoalveolar structures to the maxillary bone when the mandible is in stable position. Multiple parameters like cortical bone thickness, young's modulus, impact velocity, impactor mass, dentition and density influence the transmission of forces (18). Lucile Tuchtan et al in 2015 did a FEM study to calculate the forces transmitted to the skull through the mandible in case of mandibular trauma. Their results showed that the forces measured at the chin were 3000 N for a cortical bone thickness of 1.5 mm and 2350 N for thicknesses of 3 mm and 5 mm. The forces measured at the condyles are 1850 N, regardless of the cortical bone thickness. The forces at the condyles remained high (between 2800 N and 3600 N) for incomplete dentition and toothless models. The force at the condyles decreased to 1800 N for the complete dentition model. The forces were damped by the addition of teeth in the model. The partial dentition and toothless models yielded similar results. The toothless cases had reduced alveolar bone and therefore reduced spacing between the impactor and the condyle (19).

The fracture threshold value is considered to be between 1000 N and 1800 N, according to Allsop et al. When forces above this threshold are exerted, these forces are partly transmitted through the teeth to the maxilla, only the remaining forces are exerted on the ramus and condyle. when teeth are absent more amounts of force are exerted on the ramus condyle unit because this dampening effect is lost (20).

In figure 1 which represents a mandibular column, R represents the mandibular ramus, C and C1 represents the condyle, F is the force acting on the column and G is the posterior wall of the glenoid fossa. The force F which does not cross the threshold when applied to the mandible is dissipated partly through the dentition to the maxilla and the remaining forces are dissipated through the condyle to the cranium. If the force F1 is above the threshold and if there are missing posterior teeth then the force cannot be transmitted effectively to the maxilla and all the resultant which is transmitted to the ramus condyle unit is of higher intensity. This force pushes the mandibular column posteriorly causing the condyle C to come in contact with the posterior wall of the glenoid fossa. Here R represents the mandibular ramus, F1 is the force sufficient to cause condylar fracture. CF- compressive forces exerted on the condyle, TF- tensile force along the outer surface of ramus and FL- point of generation of flexural force. This causes formation of compressive forces (CF) along the condyle and which in turn causes tensile strain (TF) to develop along the posterior surface of the ramus. These compressive and tensile stresses cause a flexural strain (FL) along the sub condylar region which becomes the point for a fracture line to develop (Figure-2). If the force F2 is above the threshold but all posterior teeth are present then the part of the force is dissipated to the maxilla through the teeth and the remaining forces travel along the mandible which causes it to come into impact with the roof of the glenoid fossa G1. This sudden impact causes fracture to develop on the head of the condyle causing Diacapitular type of fracture. This statement is supported by an Experimental study on fractures of the mandibular condylar process by G.D.DA Fonseca in 1974. The author did experimental studies on cadavers and found that roof of the Mandibular fossa was commonly fractured in Diacapitular condylar fractures (15).

The results prove that sub condylar fractures were found in patients with absence of posterior teeth and Diacapitular fractures were common in patients with no missing teeth hence proving that number of missing posterior teeth indeed influences the location of condylar

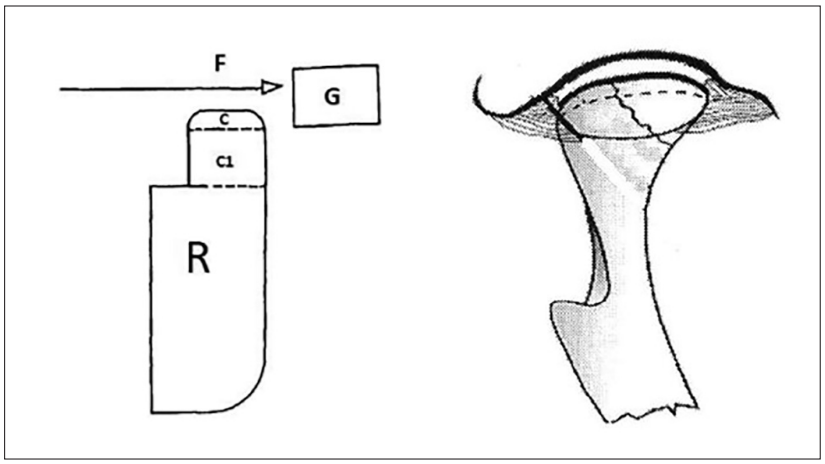

Fig. 1: R represents the mandibular ramus, C and C1 represents the condyle, F is the force acting on the column and G is the posterior wall of the glenoid fossa.

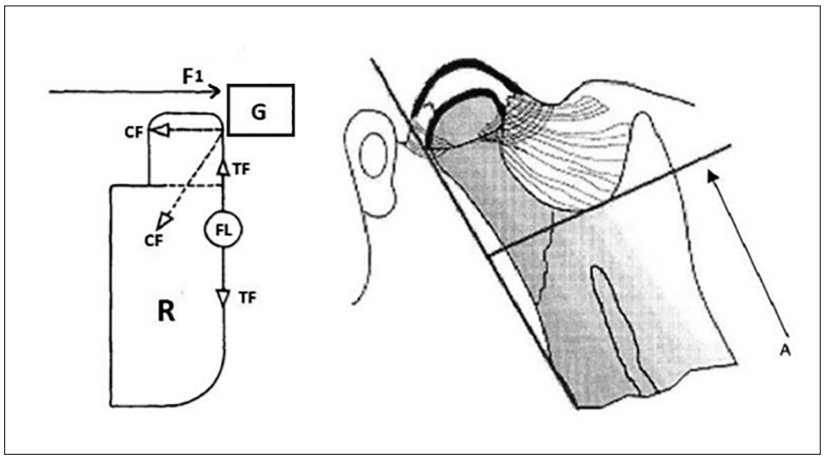

Fig. 2: R represents the mandibular ramus, F1 is the force sufficient to cause condylar fracture. CF- compressive forces exerted on the condyle, TF- tensile force along the outer surface of ramus and FL- point of generation of flexural force.

fracture line and that missing maxillary posteriors, mandibular posteriors, premolars and molars all individually showed statistical significance when correlated with the level of the fracture line.

LIMITATIONS:

The main limitation of this study is that it does not consider the position of mandible during trauma and not considering third molar endosseous position. Factors like mouth opening or closing during trauma were not taken into account. This study is based on observation, a Finite Element Model study can be done to further prove these results.

CONCLUSION:

The study demonstrated that absence of posterior teeth is indeed involved in the level of condylar fracture as hypothesized. A Validated FEM study of mandible and skull can be done to further confirm findings of the present study. The teeth are usually neglected as they are considered as an accessory aid and not an integral component of the facial skeleton. Proving that the teeth are involved in a complex mechanism which protects the Temporo- Mandibular joint from traumatic forces on the mandible will solidify their position as an integral functional component and shift the focus towards preserving rather than removing them whenever possible.

REFERENCES

1. Choi KY, Yang JD, Chung HY, Cho BC. Current concepts in the mandibular condyle fracture management part I: overview of condylar fracture. Arch Plast Surg. 2012 Jul;39(4):291-300. doi: 10.5999/aps.2012.39.4.291. Epub 2012 Jul 13. PMID: 22872830; PMCID: PMC3408272.
2. Zachariades N, Mezitis M, Mourouzis C, Papadakis D, Spanou A. Fractures of the mandibular condyle: a review of 466 cases. Literature review, reflections on treatment and proposals. Journal of CranioMaxillofacial Surgery. 2006 Oct 1;34(7):421-32
3. Weiss JP, Sawhney R. Update on mandibular condylar fracture management. Current opinion in otolaryngology & head and neck surgery. 2016 Aug 1;24(4):273-8
4. Farzan R, Farzan A, Farzan A, Karimpour M, Tolouie M. A 6-Year Epidemiological Study of Mandibular Fractures in Traumatic Patients in North of Iran: Review of 463 Patients. World J Plast Surg. 2021 Jan;10(1):71-77. doi: 10.29252/wjps.10.1.71. PMID: 33833957; PMCID: PMC8016382.
5. Zachariades N, Koumoura F, Konsolaki-Agouridaki E. Facial trauma in women resulting from violence by men. Journal of oral and maxillofacial surgery. 1990 Dec 1;48(12):1250-3
6. Mukhopadhyay S. A retrospective study of mandibular fractures in children. J Korean Assoc Oral Maxillofac Surg. 2018 Dec;44(6):269-274. doi: 10.5125/jkaoms.2018.44.6.269. Epub 2018 Dec 28. PMID: 30637240; PMCID: PMC6327018.
7. Cara AC, Gaia BF, Perrella A, Oliveira JX, Lopes PM, Cavalcanti MG. Validity of single- and multislice CT for assessment of mandibular condyle lesions. Dentomaxillofac Radiol. 2007 Jan;36(1):24-7. doi: 10.1259/dmfr/54883281. PMID: 17329584.
8. Naeem A, Gemal H, Reed D. Imaging in traumatic mandibular fractures. Quantitative imaging in medicine and surgery. 2017 Aug;7(4):46
9. Mahgoub MA, El-Sabbagh AH, Abd El-Latif EA, Elhadidy MR. Condylar Fractures: Review of 40 Cases. Ann Maxillofac Surg. 2018 Jan-Jun;8(1):19-27. doi: 10.4103/ams.ams_133_17. PMID: 29963420; PMCID: PMC6018287
10. Al-Moraissi EA, Ellis III E. Surgical treatment of adult mandibular condylar fractures provides better outcomes than closed treatment: a systematic review and meta-analysis. Journal of Oral and Maxillofacial Surgery. 2015 Mar 1;73(3):482-93
11. Chrcanovic BR. Surgical versus non-surgical treatment of mandibular condylar fractures: a meta-analysis. International journal of oral and maxillofacial surgery. 2015 Feb 1;44(2):158-79
12. Lee CY, McCullon 3rd C, Blaustein DI, Mohammadi H. Sequelae of unrecognized, untreated mandibular condylar fractures in the pediatric patient. Annals of dentistry. 1993 Jan 1;52(1):5-8.
13. Rowe NL. Fractures of the jaw in children. J. oral Surg.. 1969;27:497-507
14. Loukota RA, Eckelt U, De Bont L, Rasse M. Subclassification of fractures of the condylar process of the mandible. British journal of oral and maxillofacial surgery. 2005 Feb 1;43(1):72-3
15. Wassmund M. Über luxationsfrakturen des kiefergelenks. Dtsch Kieferch 1934;1:27e54
16. Ellis E 3rd, Palmieri C, Throckmorton GS. Further displacement of condylar process fractures after closed treatment. J Oral Maxillofac Surg 1999;59(2):120e9
17. Neff A, Kolk A, Deppe H, et al. Neue aspekte zur indikation der operativen versorgung intraartikul ärer und hoher kiefergelenklux-ationsfrakturen [New aspects for indications of surgical management of intra-articular and high temporomandibular dislocation fractures]. Mund Kiefer Gesichtschir 1999;3(1):24e9 [in German]
18. Da Fonseca, G. D. "Experimental study on fractures of the mandibular condylar process (mandibular condylar process fractures)." International journal of oral surgery 3.3 (1974): 89-101.
19. Tuchtan L, Piercecchi-Marti MD, Bartoli C, Boisclair D, Adalian P, Léonetti G, Behr M, Thollon L. Forces transmission to the skull in case of mandibular impact. Forensic science international. 2015 Jul 1;252:22-8
20. Allsop DL, Warner CY, Wille MG, Schneider DC, Nahum AM. Facial impact response—a comparison of the Hybrid III dummy and human cadaver. SAE transactions. 1988 Jan 1:1224-40.
21. Cornelius CP, Audigé L, Kunz C, Rudderman R, Buitrago-Téllez CH, Frodel J, Prein J. The Comprehensive AOCMF Classification System: Mandible Fractures-Level 3 Tutorial. Craniomaxillofac Trauma Reconstr. 2014 Dec;7(Suppl 1):S031-43. doi: 10.1055/s-0034-1389558. PMID: 25489389; PMCID: PMC4251719.

Adress:
Dr. M.S. Jothish MDS
Privafe Practioner
Tel: 6380434483
e-mail: jothishms001@gmail.com