Pyogenic granuloma of the tongue

Deena P.[1], Mugundan R.N.[2], Vinodh R.[3], Nalini Sailaja I.[4]

Rajas Dental Clinic, Ganapathy Colony, Royapettah, Chennai, Tamil Nadu, India, NM Dentistry/Oral and Maxillofacial Pathology , Orofacial care and Oral cancer center, Chennai, Tamilnadu, India, Sri Venkateswara Dental College and Hospital, Thalambur, Chennai, Tamil Nadu, India

Πυογόνο κοκκίωμα της γλώσσας. Αναφορά περίπτωσης

Deena P.[1], Mugundan R.N.[2], Vinodh R.[3], Nalini Sailaja I.[4]

Rajas Dental Clinic, Ganapathy Colony, Royapettah, Chennai, Tamil Nadu, India, NM Dentistry/Oral and Maxillofacial Pathology , Orofacial care and Oral cancer center, Chennai, Tamilnadu, India, Sri Venkateswara Dental College and Hospital, Thalambur, Chennai, Tamil Nadu, India

Case Report
Αναφορά περίπτωσης

SUMMARY: One of the most common inflammatory, non neoplastic lesion of the oral and maxillofacial region is pyogenic granuloma. It predominantly occurs on the gingival region, and rarely involves extra gingival sites of the oral cavity. A thorough knowledge of the lesion is essential for clinicopathological correlation and accurate diagnosis. Here, we present rare occurrence of pyogenic granuloma in the dorsal surface of anterior two thirds of the tongue and present a brief review of the same pathology.

KEY WORDS: *pyogenic granuloma, tongue, histopathology, oral, inflammatory hyperplasia.*

ΠΕΡΙΛΗΨΗ: Μία από τις πιο συχνές φλεγμονώδεις, μη νεοπλασματικές βλάβες της στοματικής και γναθοπροσωπικής περιοχής είναι το πυογόνο κοκκίωμα. Εμφανίζεται κυρίως στην περιοχή των ούλων και σπάνια περιλαμβάνει εξω-ουλικά σημεία της στοματικής κοιλότητας. Η ενδελεχής γνώση της βλάβης είναι απαραίτητη για την κλινικοπαθολογική συσχέτιση και την ακριβή διάγνωση. Εδώ, παρουσιάζεται μια σπάνια εμφάνιση πυογενούς κοκκιώματος στη ραχιαία επιφάνεια των πρόσθιων δύο τρίτων της γλώσσας και γίνεται μια σύντομη βιβλιογραφική ανασκόπηση της ίδιας παθολογίας.

ΛΕΞΕΙΣ ΚΛΕΙΔΙΑ: *πυογόνο κοκκίωμα, γλώσσα, ιστοπαθολογία, στόμα, φλεγμονώδης υπερπλασία*

[1] *MDS (Oral and Maxillofacial Pathology)*
[2] *MDS, Consultant – Dentistry/Oral and Maxillofacial Pathology*
[3] *MDS (Prosthetics, Crown and Bridge)*
[4] *MDS, Senior Lecturer*

Paper received: 10/4/2021 - Accepted: 31/7/2021

Παρελήφθη: 10/4/2021 - Έγινε δεκτή: 31/7/2021

INTRODUCTION

Inflammatory, hyperplastic lesions arising from the oral cavity are routinely encountered in clinical practice. One of the major obstacle in diagnosis is the striking similarity in the clinical presentation by the diverse pathoses. Poncet and Dor in 1897 first identified pyogenic granuloma (PG) as a botryomycosis hominis since they had suspected of a fungal etiology. However it was not until Crocker in 1903, who coined the term pyogenic granuloma, but it is argued that it was Hartzell in 1904 introduced the term. Hence, it is also referred as Crocker and Hartzell's disease [1].

Pyogenic granuloma comprises of 1.85% of all hyperplastic condition involving the oral cavity [2]. Almost, 3.8% to 7% of all the biopsies obtained from oral mucosa are diagnosed as PG. [3]. In the context of Indian population, PG accounts for 52.71% of the cases [4].

Causative factors for PG include trauma sustained from chronic irritation, hormonal imbalance, adverse effects from drugs, defective fillings, periodontitis and tooth brush irritation. PG is often seen in second and fifth decades of life with females predilection due to hormonal surge during pregnancy. Within the oral cavity, PG commonly involves the gingiva (75%), buccal mucosa, lips, palate and the tongue. Maxillary gingiva is more involved than mandibular gingiva. Extragingivally, it has been reported to occur on the [5]. Though they frequently occurs in the gingival regions, extra gingival occurrence of PG are rare. In this paper, we report a rare involvement of pyogenic granuloma on the anterior two thirds of the tongue.

CASE REPORT

A 64 year old female presented to our clinic with a chief complaint of swelling on her tongue for the past one mouth. She had pain associated with swelling for the past one week, for which she sought consultation. History revealed the swelling had gradually increased over the course of one month to reach its current size. She had no recollection of any traumatic event to the tongue and no other contributory medical or dental history and was not under any medication. Extra oral examination was unremarkable. Intraorally, a round ovoid, sessile, pink swelling measuring 1 x 1 cm in size in the dorsal surface of anterior 2/3rd of the tongue [Fig. 1]. The swelling was pink to greyish white in colour, firm in its consistency with no tenderness elicited on palpation [Fig. 2]. The mobility of the tongue was normal and se also presented with poor oral hygiene. Differential diagnosis of irritational fibroma, hemangioma and pyogenic granuloma was given. Excisional biopsy of the swelling was planned. Following the assessment of hematological parameters which were within normal limits. The patient first underwent to oral hygiene prophylaxis. Under local anesthesia, the swelling was excised and the specimen was submitted for histopathological evaluation. Care was taken to remove any residual fibers from the base of the swelling.

Fig. 1: Pre operative clinical photograph of the swelling involving the tongue

Fig. 2: Clinical photograph of the swelling

Histopathology revealed vascular connective tissue made of loosely arranged collagen fibers, endothelial cell proliferation and numerous capillaries of various shapes and sizes with engorged red blood corpuscles and an infiltrate of mixed inflammatory cells. Areas of fibrinopurulent membrane was seen with few exhibiting parakeratinized stratified squamous epithelium [Fig. 3, 4, 5]. The specimen was diagnosed as pyogenic granuloma. After explaining the benign nature of the lesion to the patient. She was emphasized on the importance of maintaining proper oral hygiene and to cleanse her tongue on regular basis. The biopsied site had healed without any



Fig. 3: Excised specimen submitted for histopathological analysis

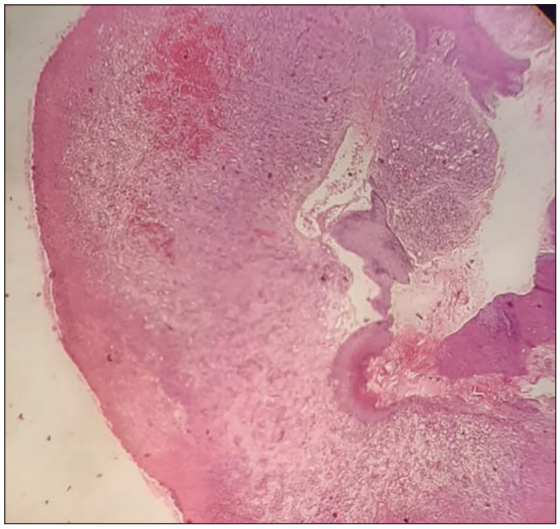

Fig. 4: Histopathological section exhibiting vascular connective tissue with engorged blood vessel, parakeratinized epithelium (4x)

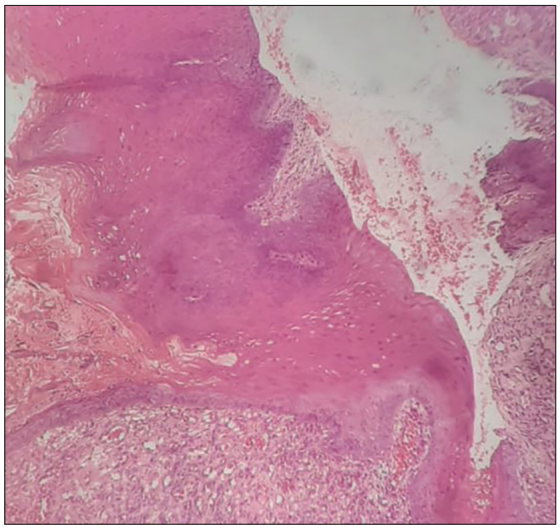

Fig. 5: Histopathological section exhibiting vascular connective tissue with diffuse extravasated red blood (10x)

events. There was no recurrence of the lesion on two year follow up [Fig. 6]

DISCUSSION

Over the course of centuries, PG has been mentioned with various terms throughout literature such as granuloma pyogenicum, eruptive hemangioma, and granuloma gravidarum. Even the current designation 'pyogenic granuloma' is often misconstrued since neither the lesion consists of any pus nor does it histologically represent a granulomatous lesion [6].

Females have a favourable predilection over males due to the action of estrogen and progesterone. Gingival apparatus is often regarded as a target organ for PG, due to the direct action of estrogen and progesterone, which upregulate the production of basic fibroblast growth factor (bFGF) and vascular endothelial growth factor (VEGF) which exaggerate inflammatory responses in gingival tissue [7, 8]. PG is often a frequent finding during pregnancy due to the hormonal surge.

Majority of the lesions occur exclusively after a traumatic insult to the local oral mucosa [9]. The insult often acts as a stimulant that results in the exuberant proliferation of connective tissue [10].

After a traumatic injury to the oral mucosa via calculus, nonspecific infection, over hanging restorations, cheek biting, previous dental extractions, exfoliating primary teeth, bone spicules, root remnants, tooth brush trauma [11] leads to the formation of granulation tissue as a part of wound healing mechanism, migration of inflammatory cells along with the proliferation of vascular endothelial cells, fibroblasts and synthesis of extracellular matrix takes places [12]. Graft vs host disease, after hematopoietic bone marrow transplantation have also been reported to cause PG [13-15].

The lesion clinically manifests as a solitary, exophytic, red, pedunculated mass or sessile plaque. Infection of the granulation tissue by microflora of oral cavity, results in the surface of the lesion getting covered by fibrin mimicking a fibrinopurulent membrane [16]. If the lesion transpires in an area subjected to constant disturbance, pain and ulceration becomes a common finding [17], which was the finding in our case, since the swelling was present in the dorsal of anterior 2/3rd of the tongue. It was subjected to constant irritation.

The histopathology reveals vascular connective tissue that exhibits lobulated solid endothelial proliferation of capillary sized blood vessels with red blood corpuscles and inflammatory cells. The surface epithelium is often parakeratotic or non-keratinized stratified squamous epithelium. Ulceration is uncommon Histological variants of involves lobular capillary hemangioma (LCH type) and non-LCH type [18].

One important differential diagnosis of PG is heman-

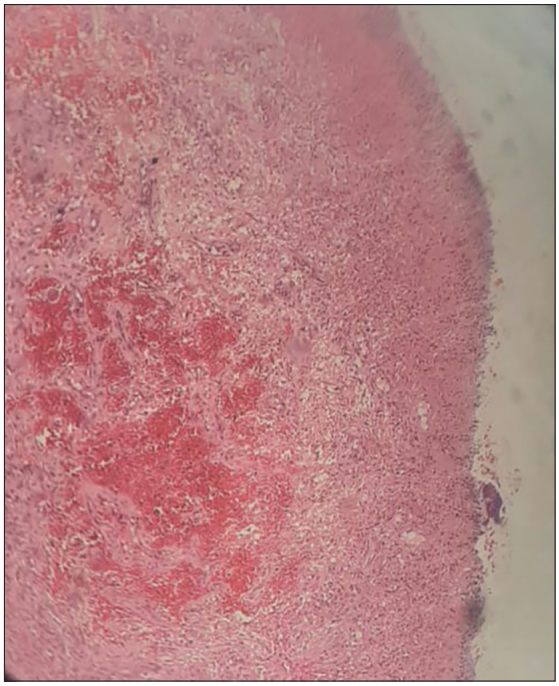

Fig. 6: Histopathological section exhibiting vascular connective tissue with engorged blood vessel and extravsated red blood cells (10x)

Fig. 7: Post operative photograph after one week

gioma which is a developmental anomaly which is in contrast to PG, which arises as a response to trauma inflicted to the underlying mucosa. PG can be differentiated from hemangioma through histopathology where the latter demonstrates histiocytoid proliferation of endothelial cells accompanied by inflammatory cell infiltrate in the connective tissue. Other differential diagnoses include bacillary angiomatosis, angiosarcoma, Kaposi's sarcoma, metastatic cancer and non-Hodgkin's lymphoma. Excision of the lesion using scalpel or Nd: YAG, CO_2 lasers, flash lamp pulsed dye lasers or cryotherapy remains the cornerstone of treatment for all cases of PG. Lasers often present with advantage of hemostasis which eliminates the need for suturing or packing post treatment [19]. Caution must be exercised to ensure the removal of the irritational factor that triggered the lesion, failure of which would eventually pave the way for recurrence. Recurrence after surgery in uncommon with a rate of 15.8%. and 16% for PG on extragingival sites However, in case of patient with pregnancy, recurrence is common [20, 21] In contrast, incomplete excision, failure elimination of etiological factors , recurrent trauma.

CONCLUSION

Although the pyogenic granuloma is a benign lesion, it should differentiated from other similar lesions to ensure a good prognosis. The patient should be educated about the causative factors and elimination of the offending agent is key in preventing future recurrence.

REFERENCES

1. Hartwell MB. Granuloma pyogenicum (botryomycosis of French authors). J Cutan Dis 1904;22:520-3.
2. Bhaskar SN, Jacoway JR. Pyogenic granuloma – clinical features, incidence, histology, and result of treatment: Report of 242 cases. J Oral Surg. 1966;24:391–8.
3. Nevile BW, Damm DD, Allen CM, Bouquot JE. Oral and Maxillofacial Pathology. 2nd Edition. W.B.Saunders; 2004. Pp. 444–44
4. Shamim T, Varghese VI, Shameena PM, Sudha S. A retrospective analysis of gingival biopsied lesions in south Indian population: 2001-2006. Med Oral Pathol Oral Cir Bucal. 2008;13:414–8.
5. Akyol MU, Yalçiner EG, Doğan AI. Pyogenic granuloma (lobular capillary hemangioma) of the tongue. Int J Pediatr Otorhinolaryngol. 2001; 58: 239–241.
6. Bouquot JE, Nikai H. Lesions of oral cavity. In: Gnepp DR, ed. Diagnostic Surgical Pathology of Head and Neck. Philadelphia, PA: W B Sanders; 2001:141–233
7. Hosseini FH, Tirgari F, Shaigan S. Immunohistochemical analysis of estrogen and progesterone receptor expression in gingival lesions. Iran J Public Health 2006;35:38-41.
8. Andrikopoulou M, Chatzistamou I, Gkilas H, Vilaras G, Sklavounou A. Assessment of angiogenic markers and female sex hormone receptors in pregnancy tumor of the gingiva. J Oral Maxillofac Surg. 2013;71(8):1376-81.
9. Pilch BZ. Head and neck surgical pathology. 2001 Lippincott Williams & Wilkins, Philadelphia, 389-390
10. Regezi JA, Sciubba JJ, Jordan RC. Oral Pathology: Clinical Pathologic Considerations. 4th ed. Philadelphia: WB Saunders; 2003. P. 115-6.
11. Patil K, Mahima VG, Lahari K. Extragingival pyogenic granuloma. Indian J Dent Res. 2006; 17: 199–202.
12. Murata M, Hara K, Saku T. Dynamic distribution of basic fibroblast growth factor during epulis formation: An immunohistochemical study in an enhanced healing process of the gingiva. J Oral Pathol Med. 1997;26:224–32.
13. Bachmeyer C, Devergie A, Mansouri S, Dubertret L, Aractingi S. Botriomycome de la langue au cours de la maladie chronique du greffon contre l'hôte [Pyogenic granuloma of the tongue in chronic graft versus host disease]. Ann Dermatol Venereol. 1996;123(9):552-4
14. Kanda Y, Arai C, Chizuka A, Suguro M, Hamaki T, Yamamoto R, Yamauchi Y, Matsuyama T, Takezako N, Shirai Y, Miwa A, Iwasaki K, Nasu M, Togawa A. Pyogenic granuloma of the tongue early after allogeneic bone marrow transplantation for multiple myeloma. Leuk Lymphoma. 2000;37(3-4):445-9.
15. Cheney-Peters D, Lund TC. Oral Pyogenic Granuloma After Bone Marrow Transplant in the Pediatric/Adolescent Population: Report of 5 Cases. J Pediatr Hematol Oncol. 2016;38(7):570-3
16. Peter A. Reichart, Hans Peter Philipsen. Color Atlas of Dental Medicine Oral Pathology. Stuttgart: Thieme. 2000:163.
17. Gordón-Núñez MA, de Vasconcelos Carvalho M, Benevenuto TG, Lopes MF, Silva LM, Galvão HC. Oral pyogenic granuloma: a retrospective analysis of 293 cases in a Brazilian population. J Oral Maxillofac Surg. 2010; 68: 2185–2188
18. R. A. Cawson, W. H. Binnie, P. M. Speight, A. W. Barrett, and J. M. Wright, Lucas Pathology of Tumors of Oral Tissues, Mosby, St. Louis, Mo, USA, 5th edition, 1998.
19. Asnaashari M, Zadsirjan S. Application of Laser in Oral Surgery. J Lasers Med Sci 2014;5(3):97-107.
20. Sapp JP, Eversole LR, Wyoscki GP. Contemporary oral and maxillofacial pathology. 2nd ed. Missouri: Mosby; 1997. Pp. 318–22
21. Jaimanti B, Ramandeep SV, Mayuresh V. Pyogenic granuloma of the hard palate: a case report and review of the literature. Ear Nose Throat J.2009;88:4.

Adress:
Dr. Deena P
Rajas Dental Clinic, 47/18, Muthu St, Ganapathy Colony, Royapettah, Chennai, Tamil Nadu 600014
Tel: +91 9841244888
e-mail: drdeena@yahoo.com